Acute exacerbations complicating interstitial lung disease

Christopher J. Ryerson[a] *and Harold R. Collard*[b]

Purpose of review
The purpose of this review is to provide an update on acute exacerbations of idiopathic pulmonary fibrosis (AE-IPF), with a specific focus on new data regarding the cause, clinical features, management and prognosis of AE-IPF. In addition, the limitations of the current definition of AE-IPF are discussed and a novel classification schema is proposed.

Recent findings
AE-IPF occurs in up to 15% of IPF patients annually and has a mortality of approximately 50%. The incidence of AE-IPF is higher in patients with worse lung function and may be increased in some populations. Emerging data suggest that exacerbations may be secondary to subclinical triggers such as infection, aspiration, mechanical injury and air pollution. Management of AE-IPF typically includes high-dose corticosteroids and antimicrobials; however, there are limited data to support these or other therapies. Prevention of AE-IPF with antifibrotic medications may be feasible and warrants further study.

Summary
AE-IPF is associated with significant morbidity and mortality; however, there remains a paucity of clinical data. The current definition of AE-IPF has limitations and a new classification schema should be considered.

Keywords
acute exacerbation, classification, diagnosis, idiopathic pulmonary fibrosis, interstitial lung disease

INTRODUCTION

Interstitial lung disease (ILD) includes a large number of diverse entities that cause inflammation or fibrosis of the lung parenchyma. The fibrotic ILDs, including idiopathic pulmonary fibrosis (IPF), chronic hypersensitivity pneumonitis and nonspecific interstitial pneumonia (NSIP), are characterized by a progressive decline in lung function and increased mortality. Up to 15% of patients with IPF experience an acute exacerbation (AE-IPF) each year [1], defined as an acute worsening of dyspnoea and lung function with an unidentifiable cause [2]. Acute respiratory worsening has also been observed in other fibrotic ILDs [3,4▪,5–10].

The goal of this review is to summarize what is known about AE-IPF and exacerbations of other fibrotic ILDs, with a focus on recent publications. We review the features, management and prognosis of acute exacerbations, and propose a novel approach to classification of acute respiratory events in this population.

DEFINITION OF ACUTE EXACERBATIONS OF IDIOPATHIC PULMONARY FIBROSIS

Widely used criteria for AE-IPF include a diagnosis of IPF with acute worsening of dyspnoea in the preceding month, coinciding with new superimposed ground glass or consolidation on high-resolution computed tomography (HRCT) [2]. The label AE-IPF is reserved for idiopathic worsening of IPF and requires exclusion of alternative causes (e.g. infection, congestive heart failure and pulmonary embolism). Many publications do not report enough detail to confidently conclude that the reported

[a]Department of Medicine, University of British Columbia, Vancouver, British Columbia, Canada and [b]Department of Medicine, University of California San Francisco, San Francisco, California, USA

Correspondence to Dr Christopher J. Ryerson, St. Paul's Hospital, 1081 Burrard St, Ward 8B, Vancouver, BC V6Z 1Y6, Canada. Tel: +1 604 806 8818; fax: +1 604 806 8839; e-mail: chris.ryerson@hli.ubc.ca

Curr Opin Pulm Med 2014, 20:436–441

DOI:10.1097/MCP.0000000000000073

Copyright © Lippincott Williams & Wilkins. Unauthorized reproduction of this article is prohibited.

KEY POINTS

- AE-IPF is an infrequent complication of IPF that is associated with high mortality.
- There is a paucity of clinical data on AE-IPF, and the prevalence, clinical features, regional differences and management require further study.
- The previous definition of AE-IPF (an acute worsening of dyspnoea and lung function with an unidentifiable cause) may no longer be the most appropriate paradigm. Researchers should consider redefining AE-IPF more broadly.

events meet these criteria, and a major problem in the field is a lack of consensus on applied definitions. Idiopathic acute worsenings have also been described in other fibrotic ILDs, including connective tissue disease-associated ILD (CTD-ILD), hypersensitivity pneumonitis and idiopathic NSIP [3,4▪,5–10].

EPIDEMIOLOGY

The incidence of AE-IPF is up to 15% per year, however with a wide variability that depends on the population being studied. Recent IPF clinical trials report an incidence of definite AE-IPF of 2–15% per year [11–14]. The rate of reported AE-IPF is higher in some observational IPF cohorts, with most of these cohorts drawn from Asian populations [1,15], or in the postsurgical setting [16,17]. Other recent studies have shown a lower incidence of AE-IPF that is comparable to rates observed in multicentre randomized trials [18]. The differences in incidence could be related to varying criteria used to define AE-IPF, different predisposing host factors in diverse populations (e.g. genetics, environmental exposures), and varying logistical challenges to event identification by study sponsors. The incidence of acute exacerbation in other fibrotic ILDs is unclear, but appears to be less frequent compared with IPF.

RISK FACTORS

Several studies have described risk factors for AE-IPF, although most of these findings have not been validated in independent cohorts. Risk factors for AE-IPF can be broadly categorized as markers of IPF severity [e.g. dyspnoea, forced vital capacity (FVC), HRCT findings [1,15,16,19▪]] and exposure of the lung to either mechanical or chemical stress. Previously described exposures that can precipitate AE-IPF include bronchoalveolar lavage [20], cryobiopsy [21], lung resection surgery [16,17], pollution [22▪], aspiration [23] and pulmonary infection [24]. Additional unvalidated risk factors for AE-IPF include a high baseline KL-6 level [25,26], increased BMI [15] and the absence of a smoking history [1]. There is a seasonal variation in some cohorts, with an increased frequency of AE-IPF in winter months [19▪,27]. A usual interstitial pneumonia pattern is associated with an increased risk of exacerbation in patients with rheumatoid arthritis [4▪]. Acute exacerbation of other fibrotic ILDs appear to have similar risk factors, but these populations are less studied.

CLINICAL FEATURES AND DIAGNOSTIC EVALUATION

By most definitions, AE-IPF is characterized by a subacute worsening of dyspnoea over the preceding 30 days, often associated with worsening cough and systemic or constitutional symptoms. Occasionally, up to 60 days of symptoms are allowed. An acute exacerbation can be the presenting manifestation of IPF, but more commonly occurs in established, later-stage disease [1]. HRCT demonstrates typical features of fibrotic ILD, with superimposed bilateral ground glass or consolidative changes [28]. Clinical and radiological features are similar in acute exacerbations of other fibrotic ILDs [5,29].

Diagnosis of AE-IPF requires careful evaluation for potential causes. This typically includes bronchoscopy with bronchoalveolar lavage to evaluate for the presence of infection. Bronchoscopy can further worsen gas exchange and may not be appropriate in nonintubated patients with severe hypoxemia. Noninvasive microbiological studies are appropriate in this situation, including analysis of sputum and nasopharyngeal specimens. Transbronchial biopsies are rarely helpful and should be avoided owing to their low yield and high risk of complications. When performed, surgical lung biopsy demonstrates both diffuse alveolar damage and organizing pneumonia on the background of underlying usual interstitial pneumonia [8,30,31]. Lung biopsy findings rarely alter management of AE-IPF and should generally be discouraged based on the significant morbidity and mortality in this population.

MANAGEMENT

The management of AE-IPF includes supportive care, corticosteroids and treatment of reversible causes. Many patients with AE-IPF require mechanical ventilation due to severe hypoxemia; however, this may not be appropriate in some patients and should be assessed on a case-by-case basis considering patient wishes and the potential for recovery. Pharmacological management of AE-IPF commonly includes

Copyright © Lippincott Williams & Wilkins. Unauthorized reproduction of this article is prohibited.

high-dose corticosteroids and is recommended by the recent consensus guidelines based on admittedly very low quality data [32]. There are two approaches commonly used. The first borrows from the acute respiratory distress syndrome (ARDS) literature and prescribes moderate doses of prednisone (e.g. 40–60 mg) or equivalent for 2–3 weeks with the idea that this will help the resolution of acute lung injury. The second uses extreme doses of prednisone (e.g. 0.5–1.0 g daily) or equivalent for 3–5 days (then tapered based on clinical response) with the idea that any organizing pneumonia contributing to respiratory worsening should respond. Additional medications have been studied, including polymyxin B-immobilized fibre cartridge [33], tacrolimus [34] and cyclosporine A [35]; however, there are insufficient data to justify their use and these are not currently recommended. Chronic use of antifibrotic medications such as nintedanib may have a role in preventing AE-IPF [12]. Patients in the INPULSIS-2 trial who were treated with nintedanib had a significant increase in the time to the first investigator-reported AE-IPF (hazard ratio, 0.38; 95% confidence interval, 0.19–0.77; $P = 0.005$), although this benefit was not replicated in the INPULSIS-1 trial [36▪]. Taken together, the INPULSIS trials show an inconsistent effect of nintedanib on AE-IPF that requires further study.

Patients with AE-IPF are commonly prescribed antibiotics on the basis of the frequent inability to confidently exclude an acute bacterial infection. A single randomized trial of 61 patients with AE-IPF suggested that pro-calcitonin may be helpful in guiding antibiotic use [37▪]; however, this requires further study before adoption into clinical practice. Standard infection control measures (hand washing, influenza and pneumococcal vaccination) should be employed as preventive measures. Chronic antireflux therapy may help prevent AE-IPF [38▪], particularly in patients with evidence of gastroesophageal reflux. It is unknown whether all patients with AE-IPF should receive antireflux medication.

PROGNOSIS

Most cohort studies of AE-IPF report that the short-term mortality is at least 50% [1,18,39], and in-hospital mortality exceeds 90% for patients admitted to an ICU [40,41]. Acute exacerbations are therefore a major prognostic factor, and respiratory hospitalization is a well described independent risk factor for mortality [42]. Several small studies have evaluated potential predictors of prognosis in AE-IPF, showing worse survival in patients with higher serum KL-6 [18,26], worse oxygenation [18], greater total extent of HRCT abnormality (ground glass, consolidation and traction bronchiectasis) [18, 43,44] and diffuse disease on HRCT (compared with peripheral or multifocal involvement) [9,28]. Despite similar clinical features [5], patients with AE-IPF have worse survival than patients with acute exacerbation of other fibrotic ILDs [45].

DISCUSSION AND FUTURE DIRECTIONS

Recent publications have provided additional insight into the clinical features and biology of AE-IPF; however, there remain several important unanswered questions.

Should the term acute exacerbations of idiopathic pulmonary fibrosis be limited to idiopathic respiratory worsening?

AE-IPF is currently defined as an idiopathic event, and its diagnosis requires thorough evaluation to exclude potential causes [2]. This definition is based on the assumption that AE-IPF represents an inherent acceleration in IPF that occurs in some patients during the natural course of their disease, and that the identification of this event has clinical relevance. Supporting this hypothesis is the absence of identifiable cause, and the lack of infectious or inflammatory gene expression patterns or biomarker levels in idiopathic AE-IPF patients [46,47]. Alternatively, it is possible that AE-IPF represents lung injury from a specific insult (e.g. infection, aspiration) that is clinically occult and that causes more severe damage because of the underlying host lung's IPF.

We believe the evidence is beginning to argue against AE-IPF, as currently defined, as a biologically distinct entity with unique clinical relevance. There is evidence (summarized above) that infection and aspiration may play a major role in precipitating AE-IPF, and that respiratory worsenings of any type (idiopathic or due to known cause) look and behave the same [1,19▪]. There are additional practical considerations. Patients with acute respiratory worsening often present to the clinic or hospital several days or weeks after symptom onset, and an infectious workup done at this time will likely be negative, as many viral infections will have already been cleared. In addition, patients with IPF are often prescribed antimicrobials early in the course of an exacerbation and these will reduce the yield of bronchoscopy. It is often difficult to identify aspiration events that can lead to an acute respiratory worsening. Finally, there are a large number of patients with acute respiratory worsening who are unable to undergo bronchoscopy (or even imaging) due to significant hypoxemia, and therefore cannot

Copyright © Lippincott Williams & Wilkins. Unauthorized reproduction of this article is prohibited.

be classified as AE-IPF. Taken together, these findings raise theoretical and practical concerns with the current definition of AE-IPF.

We believe that restricting AE-IPF to idiopathic cases is not supported by emerging etiologic data and has proven difficult to implement. This deserves careful consideration by the IPF community moving forward. One potential modification would be to consider acute worsening of IPF under three major categories as follows (Fig. 1):

(1) AE-IPF: An acute respiratory worsening of IPF characterized by increased dyspnoea over 30 days and bilateral ground glass/consolidation on HRCT scan. These events can be subcategorized into idiopathic AE-IPF and AE-IPF secondary to an identified trigger.
(2) Idiopathic worsening of IPF: An acute respiratory worsening of IPF characterized by increased dyspnoea over 30 days without superimposed ground glass or consolidation on HRCT scan.
(3) Acute worsening from extra-parenchymal cause: An acute increase in dyspnoea over 30 days with an identifiable extra-pulmonary trigger (e.g. pulmonary embolism, congestive heart failure, pneumothorax, effusion, anxiety).

Considering acute respiratory worsening according to these categories provides a more practical approach to these clinically relevant events. Appropriate patients without a full evaluation can be classified using the same approach with a 'suspected' modifier. This classification schema also directly fits the concept that AE-IPF represents lung injury from an occult secondary cause, without losing the ability to further study the biology, clinical features and management of idiopathic events.

How carefully should infection (and other potential triggers) be looked for in practice?

It is difficult to clinically exclude infection in patients with AE-IPF. Bronchoscopic evaluation for pulmonary infection is an important component of the diagnostic process, although it is primarily helpful to rule in (not out) a pulmonary infection. Despite its high specificity in diagnosing pulmonary infection, bronchoscopy is relatively insensitive, particularly in the context of recent antibiotic use [48], and it is therefore an imperfect test for diagnosing an idiopathic AE-IPF. Surgical lung biopsy typically shows diffuse alveolar damage with or without organizing pneumonia on a background of usual interstitial pneumonia [8,30,31]. Diffuse alveolar damage and organizing pneumonia are etiologically nonspecific patterns that can be seen as a result of many potential causes of acute lung injury. Therefore, findings on surgical lung biopsy rarely if ever help in identifying the underlying cause of respiratory worsening. On the basis of the above, many clinicians decide that bronchoscopy and surgical lung biopsy are high risk and unlikely to

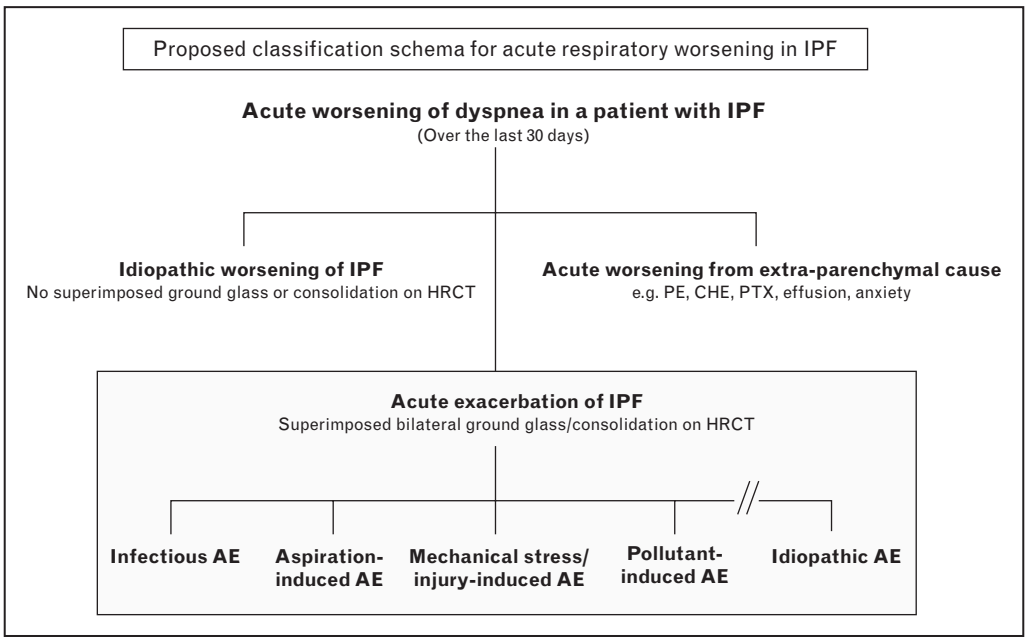

FIGURE 1. Proposed classification schema for acute respiratory worsening in IPF. AE, acute exacerbation; CHF, congestive heart failure; HRCT, high-resolution computed tomography; IPF, idiopathic pulmonary fibrosis; PE, pulmonary embolism; PTX, pneumothorax.

Copyright © Lippincott Williams & Wilkins. Unauthorized reproduction of this article is prohibited.

change their management in patients with AE-IPF. As we reassess the appropriateness of defining AE-IPF as idiopathic, it is important to also reconsider how the aggressive search for infection (or other precipitants such as aspiration) alters clinical care and improves patient outcomes.

Should these considerations apply only to idiopathic pulmonary fibrosis or to all fibrotic interstitial lung diseases?

Established criteria for AE-IPF refer only to IPF, however there are clinical and radiological similarities with acute worsenings of other fibrotic ILDs, including CTD-ILD, hypersensitivity pneumonitis, and idiopathic NSIP [3,4▪,5–10]. Despite these similarities, there are differences in IPF biology that suggest there may be underlying differences between these conditions. For example, dysfunctional alveolar repair mechanisms in IPF could increase the risk of acute exacerbation by impairing the ability of the IPF lung to respond to minor injuries that would be readily repaired in other ILDs. The severity and prognosis of respiratory events could also be worse in IPF for this reason. Given these potential differences, future studies comparing AE-IPF to other fibrotic ILDs could provide insight into the pathogenesis of acute exacerbation by identifying commonalities or differences that exist across subtypes. Classifying acute respiratory worsening of non-IPF fibrotic ILDs using the framework described above would facilitate future study of these rare events by standardizing definitions across cohorts.

CONCLUSION

AE-IPF is an infrequent complication of IPF that is associated with high mortality. There is a paucity of clinical data on AE-IPF, and the prevalence, clinical features and regional differences remain uncertain. The management of AE-IPF with high-dose corticosteroids and other more novel therapies requires further study.

AE-IPF, as currently defined, is idiopathic, but this may no longer be the most appropriate paradigm. It remains unknown whether idiopathic AE-IPF is a distinct biological and clinical entity, but emerging evidence suggests that this may not be the case. We believe that researchers should consider redefining AE-IPF more broadly, as described earlier. The standardized application of these criteria to patients with IPF and other fibrotic ILD subtypes will facilitate more comprehensive and, we hope, informative future study of these clinically significant events.

Acknowledgements

No funding was provided for this study.

Conflicts of interest

The authors have no conflicts of interest.

REFERENCES AND RECOMMENDED READING

Papers of particular interest, published within the annual period of review, have been highlighted as:
▪ of special interest
▪▪ of outstanding interest

1. Song JW, Hong SB, Lim CM, *et al.* Acute exacerbation of idiopathic pulmonary fibrosis: incidence, risk factors and outcome. Eur Respir J 2011; 37:356–363.
2. Collard HR, Moore BB, Flaherty KR, *et al.* Acute exacerbations of idiopathic pulmonary fibrosis. Am J Respir Crit Care Med 2007; 176:636–643.
3. Song JW, Lee HK, Lee CK, *et al.* Clinical course and outcome of rheumatoid arthritis-related usual interstitial pneumonia. Sarcoidosis Vasc Diffuse Lung Dis 2013; 30:103–112.
4. ▪ Hozumi H, Nakamura Y, Johkoh T, *et al.* Acute exacerbation in rheumatoid arthritis-associated interstitial lung disease: a retrospective case control study. BMJ Open 2013; 3:e003132.

This is a retrospective analysis of 51 patients with ILD secondary to rheumatoid arthritis who were followed for a median of 8.5 years from the time of diagnosis. Using similar criteria to the proposed definition of AE-IPF, 11 patients (22%) developed an acute exacerbation of their ILD, with a 1-year incidence of 2.8%. Acute exacerbations were more common in rheumatoid arthritis patients who had radiological features of usual interstitial pneumonia.

5. Tachikawa R, Tomii K, Ueda H, *et al.* Clinical features and outcome of acute exacerbation of interstitial pneumonia: collagen vascular diseases-related versus idiopathic. Respiration 2012; 83:20–27.
6. Suda T, Kaida Y, Nakamura Y, *et al.* Acute exacerbation of interstitial pneumonia associated with collagen vascular diseases. Respir Med 2009; 103:846–853.
7. Park IN, Kim DS, Shim TS, *et al.* Acute exacerbation of interstitial pneumonia other than idiopathic pulmonary fibrosis. Chest 2007; 132:214–220.
8. Churg A, Muller NL, Silva CI, Wright JL. Acute exacerbation (acute lung injury of unknown cause) in UIP and other forms of fibrotic interstitial pneumonias. Am J Surg Pathol 2007; 31:277–284.
9. Silva CI, Muller NL, Fujimoto K, *et al.* Acute exacerbation of chronic interstitial pneumonia: high-resolution computed tomography and pathologic findings. J Thorac Imaging 2007; 22:221–229.
10. Miyazaki Y, Tateishi T, Akashi T, *et al.* Clinical predictors and histologic appearance of acute exacerbations in chronic hypersensitivity pneumonitis. Chest 2008; 134:1265–1270.
11. Idiopathic Pulmonary Fibrosis Clinical Research N. Raghu G, Anstrom KJ, King TE Jr, *et al.* Azathioprine, and N-acetylcysteine for pulmonary fibrosis. N Engl J Med 2012; 366:1968–1977.
12. Richeldi L, Costabel U, Selman M, *et al.* Efficacy of a tyrosine kinase inhibitor in idiopathic pulmonary fibrosis. N Engl J Med 2011; 365:1079–1087.
13. King TE Jr, Brown KK, Raghu G, *et al.* BUILD-3: a randomized, controlled trial of bosentan in idiopathic pulmonary fibrosis. Am J Respir Crit Care Med 2011; 184:92–99.
14. King TE Jr, Albera C, Bradford WZ, *et al.* Effect of interferon gamma-1b on survival in patients with idiopathic pulmonary fibrosis (INSPIRE): a multicentre, randomised, placebo-controlled trial. Lancet 2009; 374:222–228.
15. Kondoh Y, Taniguchi H, Katsuta T, *et al.* Risk factors of acute exacerbation of idiopathic pulmonary fibrosis. Sarcoidosis Vasc Diffuse Lung Dis 2010; 27:103–110.
16. Sugiura H, Takeda A, Hoshi T, *et al.* Acute exacerbation of usual interstitial pneumonia after resection of lung cancer. Ann Thorac Surg 2012; 93:937–943.
17. Mizuno Y, Iwata H, Shirahashi K, *et al.* The importance of intraoperative fluid balance for the prevention of postoperative acute exacerbation of idiopathic pulmonary fibrosis after pulmonary resection for primary lung cancer. Eur J Cardiothorac Surg 2012; 41:e161–e165.
18. Kishaba T, Tamaki H, Shimaoka Y, *et al.* Staging of acute exacerbation in patients with idiopathic pulmonary fibrosis. Lung 2014; 192:141–149.
19. ▪ Collard HR, Yow E, Richeldi L, *et al.,* Investigators IP. Suspected acute exacerbation of idiopathic pulmonary fibrosis as an outcome measure in clinical trials. Resp Res 2013; 14:73.

This is a posthoc analysis of a randomized placebo-controlled trial of 180 advanced IPF patients who were followed for 24 weeks. Acute respiratory worsening was identified in 35 patients, including four with definite and 14 with suspected idiopathic AE-IPF. Definite and suspected idiopathic AE-IPF had similar clinical features, and the authors suggest that both definite and suspected events should be captured as a potential endpoint for future clinical trials.

Copyright © Lippincott Williams & Wilkins. Unauthorized reproduction of this article is prohibited.

20. Sakamoto K, Taniguchi H, Kondoh Y, *et al.* Acute exacerbation of IPF following diagnostic bronchoalveolar lavage procedures. Resp Med 2012; 106:436–442.

21. Casoni GL, Tomassetti S, Cavazza A, *et al.* Transbronchial lung cryobiopsy in the diagnosis of fibrotic interstitial lung diseases. PLoS One 2014; 9: e86716.

22. ■ Johannson KA, Vittinghoff E, Lee K, *et al.* Acute exacerbation of idiopathic pulmonary fibrosis associated with air pollution exposure. Eur Resp J 2014; 43:1124–1131.

This is a retrospective analysis of 436 Korean patients with IPF, including 75 who had at least one acute exacerbation. Patient address was linked to data from regional air quality monitoring systems, showing that AE-IPF was associated with an antecedent increase in local levels of ozone and nitrogen dioxide. These findings suggest that some acute exacerbations may be triggered by air pollution.

23. Lee JS, Song JW, Wolters PJ, *et al.* Bronchoalveolar lavage pepsin in acute exacerbation of idiopathic pulmonary fibrosis. Eur Resp J 2012; 39:352–358.

24. Wootton SC, Kim DS, Kondoh Y, *et al.* Viral infection in acute exacerbation of idiopathic pulmonary fibrosis. Am J Resp Crit Care Med 2011; 183:1698–1702.

25. Kishaba T, Shimaoka Y, Fukuyama H, *et al.* A cohort study of mortality predictors and characteristics of patients with combined pulmonary fibrosis and emphysema. BMJ Open 2012; 2.

26. Ohshimo S, Ishikawa N, Horimasu Y, *et al.* Baseline KL-6 predicts increased risk for acute exacerbation of idiopathic pulmonary fibrosis. Resp Med 2014; 108:1031–1039.

27. Simon-Blancal V, Freynet O, Nunes H, *et al.* Acute exacerbation of idiopathic pulmonary fibrosis: outcome and prognostic factors. Respiration 2012; 83:28–35.

28. Akira M, Kozuka T, Yamamoto S, Sakatani M. Computed tomography findings in acute exacerbation of idiopathic pulmonary fibrosis. Am J Resp Crit Care Med 2008; 178:372–378.

29. Perez-Alvarez R, Perez-de-Lis M, Diaz-Lagares C, *et al.* Interstitial lung disease induced or exacerbated by TNF-targeted therapies: analysis of 122 cases. Semin Arthritis Rheum 2011; 41:256–264.

30. Kim DS, Park JH, Park BK, *et al.* Acute exacerbation of idiopathic pulmonary fibrosis: frequency and clinical features. Eur Resp J 2006; 27: 143–150.

31. Ambrosini V, Cancellieri A, Chilosi M, *et al.* Acute exacerbation of idiopathic pulmonary fibrosis: report of a series. Eur Resp J 2003; 22:821–826.

32. Raghu G, Collard HR, Egan JJ, *et al.* An official ATS/ERS/JRS/ALAT statement: idiopathic pulmonary fibrosis: evidence-based guidelines for diagnosis and management. Am J Resp Crit Care Med 2011; 183:788–824.

33. Abe S, Azuma A, Mukae H, *et al.* Polymyxin B-immobilized fiber column (PMX) treatment for idiopathic pulmonary fibrosis with acute exacerbation: a multicenter retrospective analysis. Int Med 2012; 51:1487–1491.

34. Horita N, Akahane M, Okada Y, *et al.* Tacrolimus and steroid treatment for acute exacerbation of idiopathic pulmonary fibrosis. Int Med 2011; 50:189–195.

35. Sakamoto S, Homma S, Miyamoto A, *et al.* Cyclosporin A in the treatment of acute exacerbation of idiopathic pulmonary fibrosis. Int Med 2010; 49:109–115.

36. ■ Richeldi L, du Bois RM, Raghu G, *et al.* Efficacy and safety of nintedanib in idiopathic pulmonary fibrosis. N Engl J Med 2014; 370:2071–2082.

This is a report of two phase 3 randomized controlled trials that compared nintedanib with placebo in 1066 patients with mild to moderate IPF. Patients in the INPULSIS-2 trial who were treated with nintedanib had a significant increase in the time to the first investigator-reported AE-IPF, although this benefit was not replicated in the INPULSIS-1 trial. These findings suggest that nintedanib may help prevent AE-IPF, although the inconsistency between these two trials indicates the need for additional study.

37. ■ Ding J, Chen Z, Feng K. Procalcitonin-guided antibiotic use in acute exacerbations of idiopathic pulmonary fibrosis. Int J Med Sci 2013; 10:903–907.

This is a prospective randomized study of 78 patients with AE-IPF who were randomized to receive routine antimicrobial treatment or antibiotics guided by procalcitonin level. The median duration of antibiotics was lower in the procalcitonin group, and there were no differences in duration of mechanical ventilation or mortality. These are interesting findings; however, additional research is warranted before adoption into clinical practice.

38. ■ Lee JS, Collard HR, Anstrom KJ, *et al.* Antiacid treatment and disease progression in idiopathic pulmonary fibrosis: an analysis of data from three randomised controlled trials. Lancet Resp Med 2013; 1:369–376.

This is a posthoc analysis of 242 patients randomized to the placebo group of three randomized controlled trials of IPF. The authors showed that the 124 patients on a proton pump inhibitor or H2 blocker at enrolment had a smaller decline in FVC at 30 weeks, than patients not on either of these medications. Although retrospective, this study suggests antiacid therapy may slow progression of fibrosis in patients with IPF.

39. Agarwal R, Jindal SK. Acute exacerbation of idiopathic pulmonary fibrosis: a systematic review. Eur J Intern Med 2008; 19:227–235.

40. Al-Hameed FM, Sharma S. Outcome of patients admitted to the intensive care unit for acute exacerbation of idiopathic pulmonary fibrosis. Canad Resp J 2004; 11:117–122.

41. Rangappa P, Moran JL. Outcomes of patients admitted to the intensive care unit with idiopathic pulmonary fibrosis. Crit Care Resusc 2009; 11:102–109.

42. du Bois RM, Weycker D, Albera C, *et al.* Ascertainment of individual risk of mortality for patients with idiopathic pulmonary fibrosis. Am J Resp Crit Care Med 2011; 184:459–466.

43. Fujimoto K, Taniguchi H, Johkoh T, *et al.* Acute exacerbation of idiopathic pulmonary fibrosis: high-resolution CT scores predict mortality. Eur Radiol 2012; 22:83–92.

44. Ichikado K. High-resolution computed tomography findings of acute respiratory distress syndrome, acute interstitial pneumonia, and acute exacerbation of idiopathic pulmonary fibrosis. Semin Ultrasound CT MR 2014; 35:39–46.

45. Huie TJ, Olson AL, Cosgrove GP, *et al.* A detailed evaluation of acute respiratory decline in patients with fibrotic lung disease: aetiology and outcomes. Respirology 2010; 15:909–917.

46. Konishi K, Gibson KF, Lindell KO, *et al.* Gene expression profiles of acute exacerbations of idiopathic pulmonary fibrosis. Am J Resp Crit Care Med 2009; 180:167–175.

47. Collard HR, Calfee CS, Wolters PJ, *et al.* Plasma biomarker profiles in acute exacerbation of idiopathic pulmonary fibrosis. Am J Physiol Lung Cell Mol Physiol 2010; 299:L3–7.

48. Prats E, Dorca J, Pujol M, *et al.* Effects of antibiotics on protected specimen brush sampling in ventilator-associated pneumonia. Eur Respir J 2002; 19:944–951.

Copyright © Lippincott Williams & Wilkins. Unauthorized reproduction of this article is prohibited.